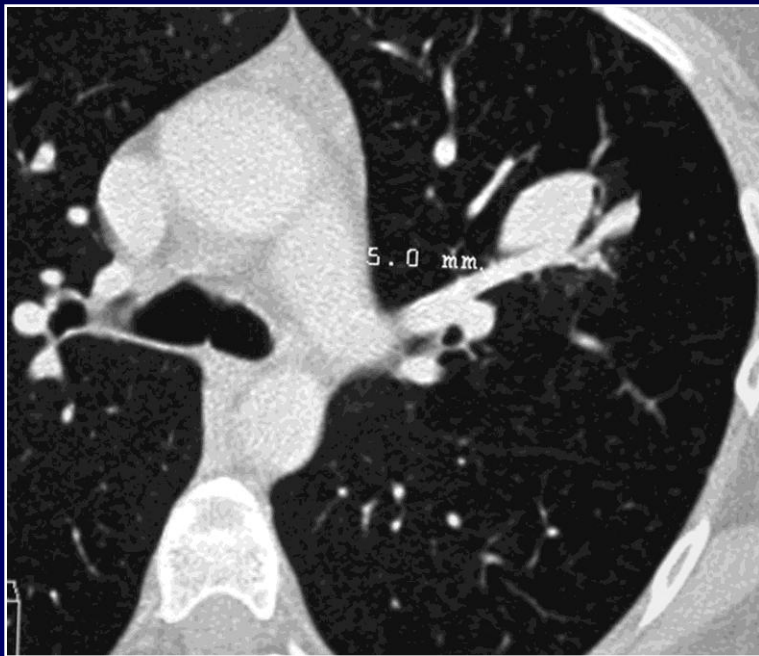
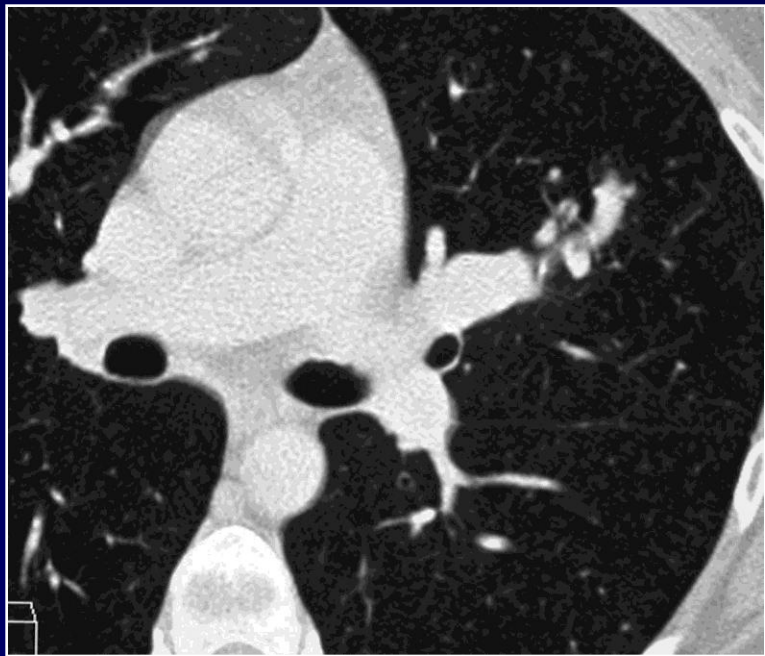
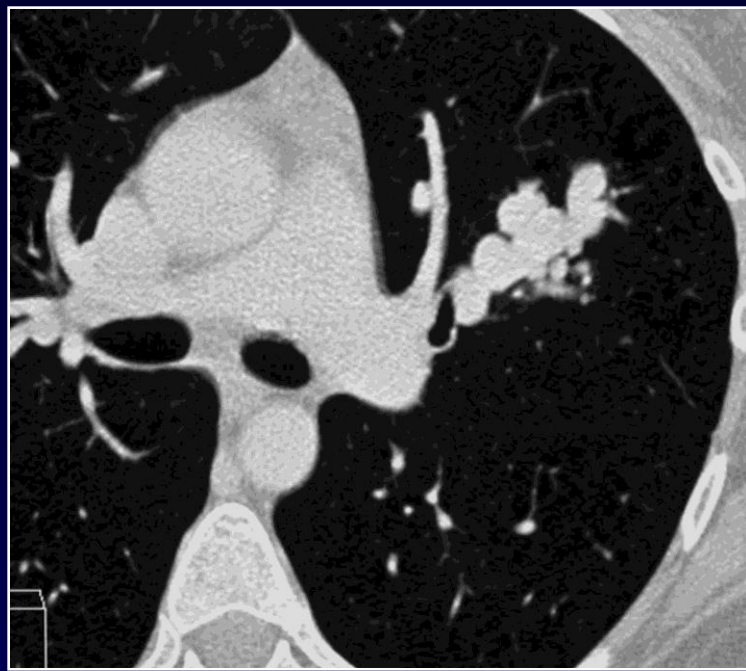
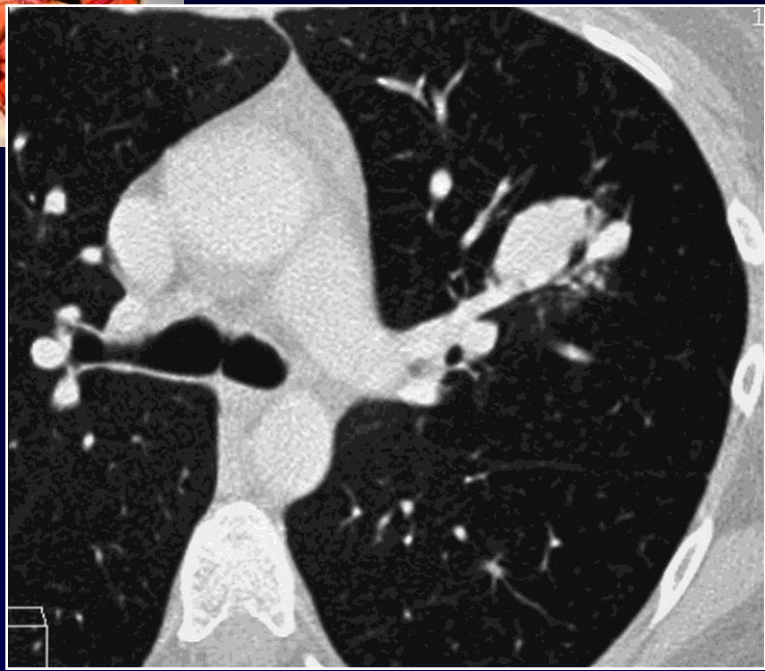


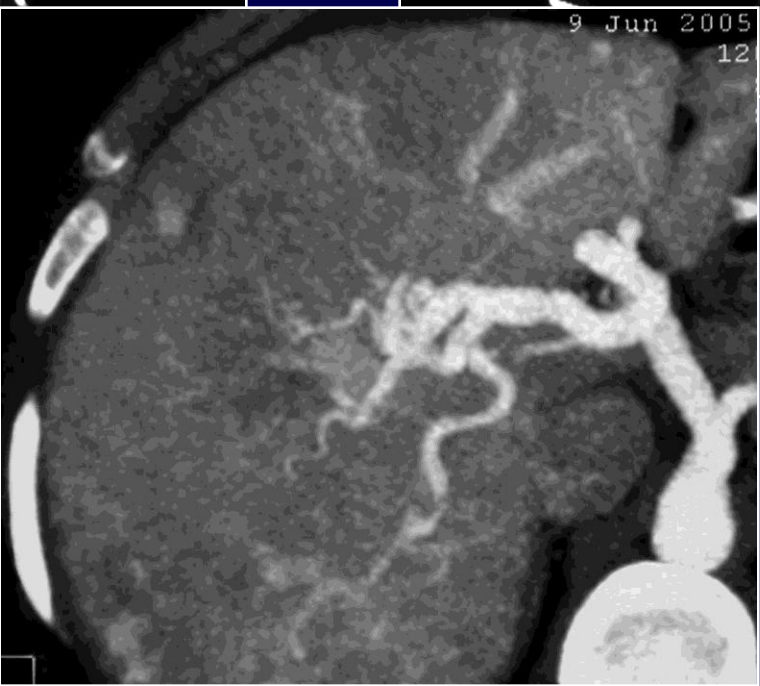
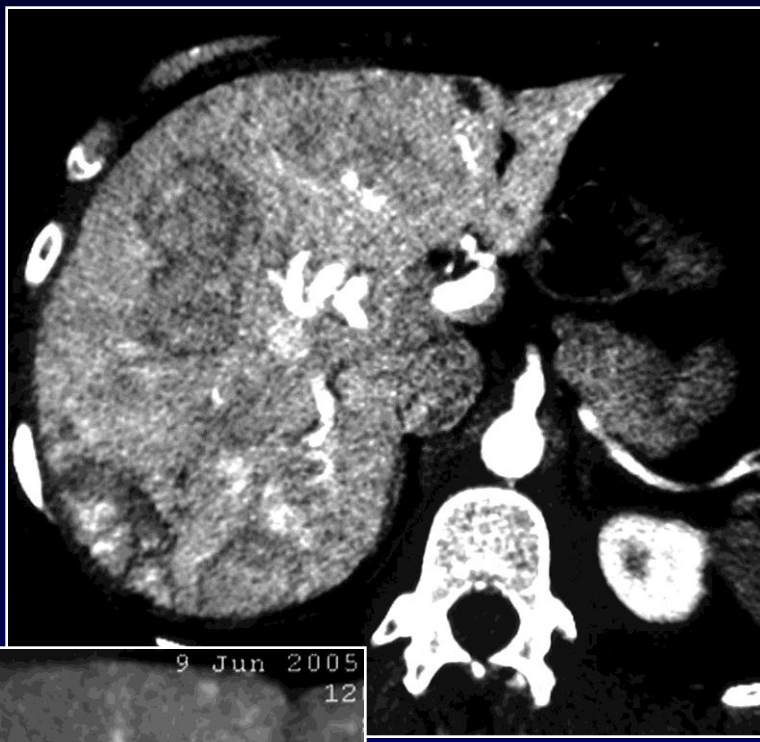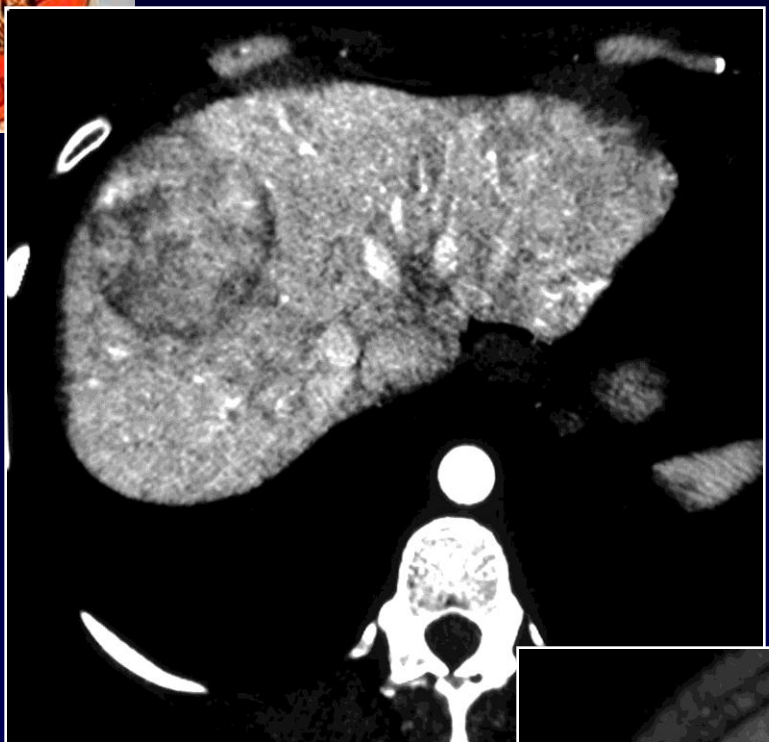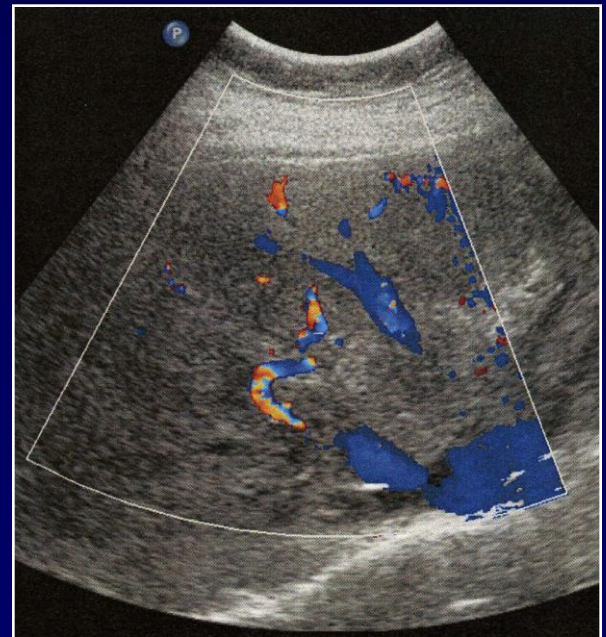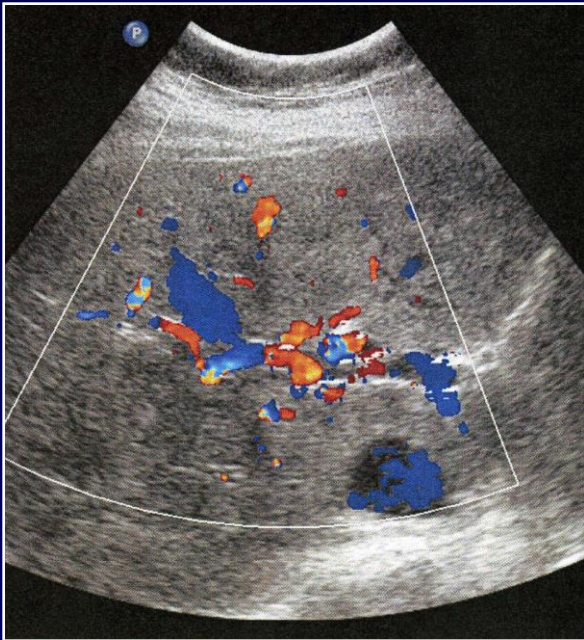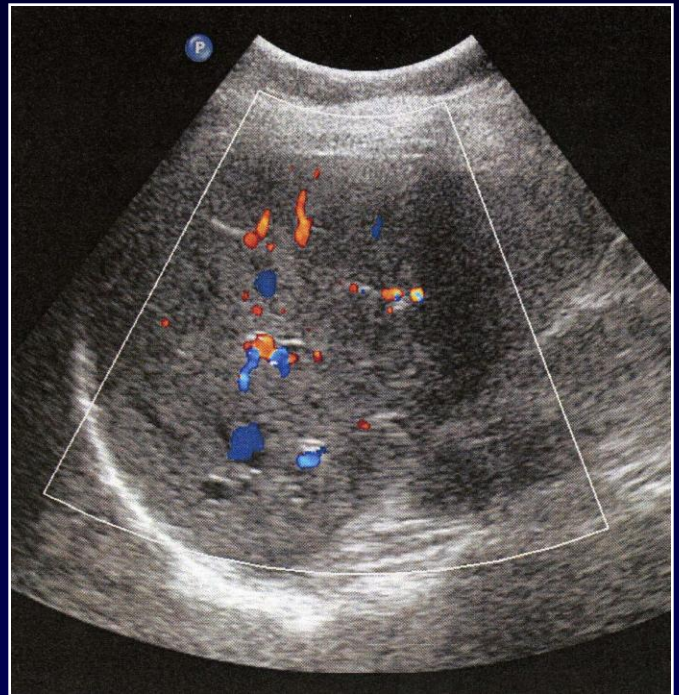
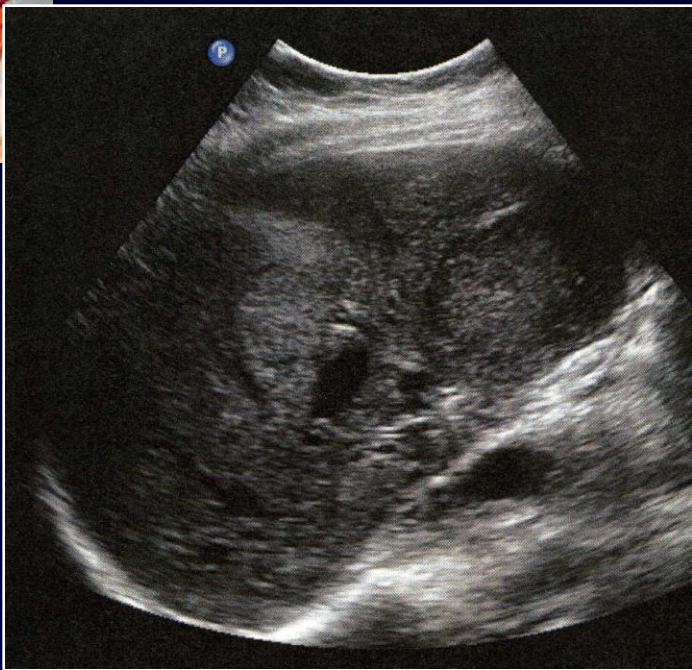
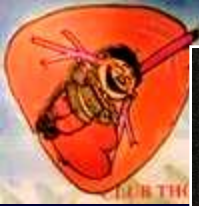**P. FAJADET**

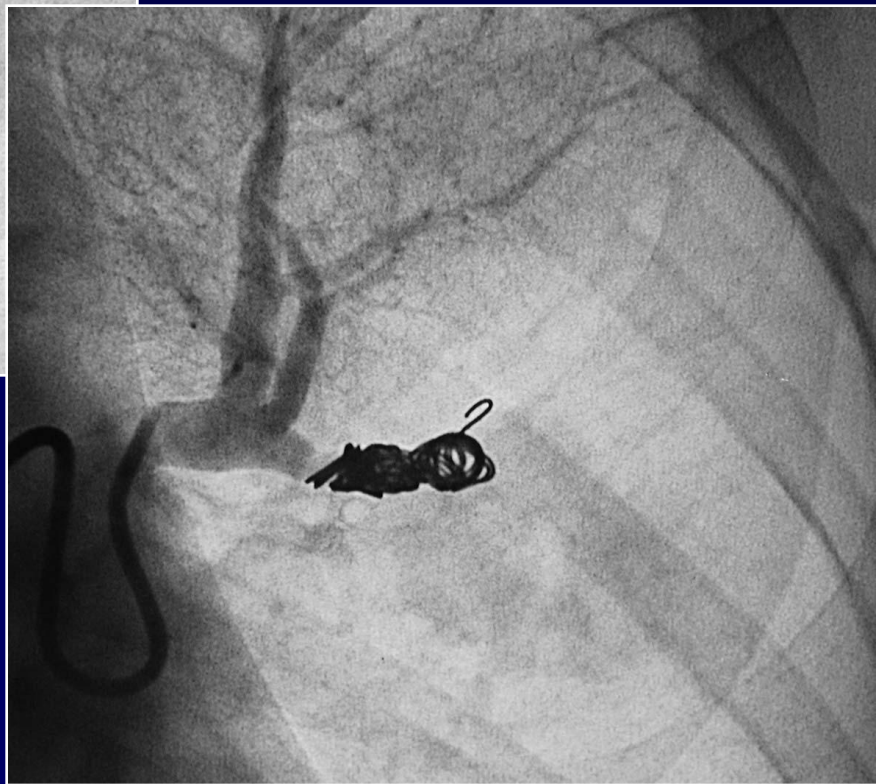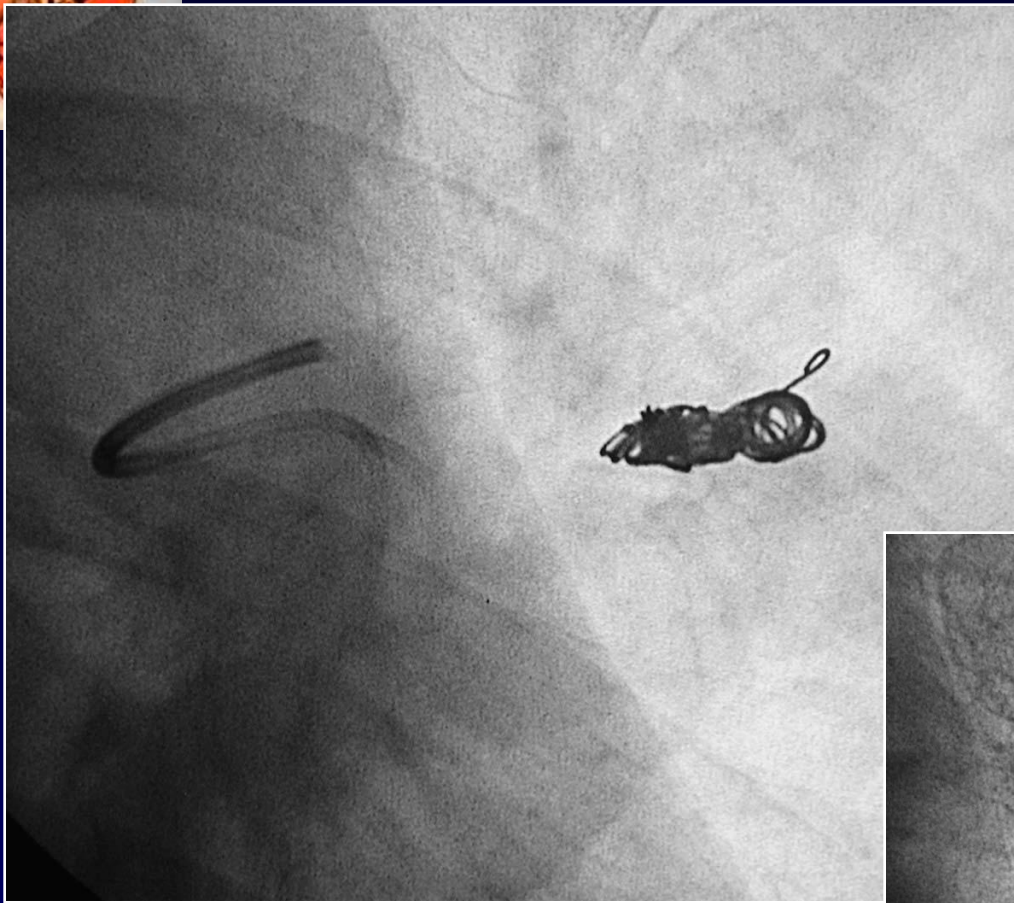
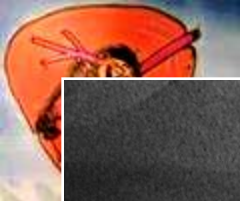
**Femme de 37 ans**

**Découverte fortuite**



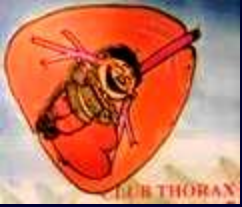







**Diagnostic ?**



# Maladie de Rendu Osler

**MAV pulmonaire avec aspect de pseudo HFN  
hépatiques**

**Vaso-occlusion de la MAV pulmonaire**